

Calyceal Diverticulum: A Case Report

Stoyanka Dineva¹, Nikolay Halachev², Nencho Smilov²

¹(Department Of Radiology, Medical Institute Of Ministry Of Interior – Sofia)

²(Department Of Urology, Medical Institute Of Ministry Of Interior - Sofia)

Abstract: A calyceal diverticulum is usually identified during urological investigation for haematuria or recurrent urinary tract infection. Calyceal diverticula might be diagnosed as an incidental finding or can be symptomatic owing to recurrent urinary tract infection (UTI) or stone formation within the diverticulum, both of which are precipitated by urinary stasis within the diverticulum. Other common presenting features include ipsilateral flank pain and haematuria. The increasing use of cross-sectional imaging, in particular CT urography, has resulted in the increased detection of calyceal diverticula, although the majority of calyceal diverticula can be diagnosed by ultrasound. Intravenous urogram (IVU) and retrograde studies can be required to confirm diagnosis.

We report a rare case of a disappearing cystic mass of the kidney. Pyelocalyceal diverticulum has to be considered in the differential diagnosis of patients with pyelonephritis and a space-occupying lesion of the kidney. Initial conservative therapy with antibiotics helps to determine the definitive diagnosis.

Keywords : Calyceal diverticulum, renal calyx, CT urography

I. Introduction

The term “calyceal diverticulum” was first suggested by Prather in 1941 [1] and, since then, a number of potential aetiologies have been described in the literature.

Pyelocalyceal diverticulum is a urine-containing eventration of the upper collecting system communicating with the main collecting system via a narrow channel, lined by non-secretory transitional cell epithelium and is surrounded by a layer of muscularis mucosae [2],[3]. Pyelocalyceal diverticulae are usually asymptomatic but may present with symptoms of urinary tract obstruction when complicated by calculi or of infection, when the latter supervenes [4],[5]. The cyst was situated in the renal parenchyma with its medial margin abutting the renal sinus.

The incidence is 2.1 to 4.5 per 1000 IVUs and are bilateral in 3% of cases. [6]

Calyceal diverticulum is a urine-containing cavity within the renal parenchyma communicating with the collecting system through a narrow channel and is lined by transitional epithelium.[2]

The diverticulum may be congenital, secondary to trauma or a complication of previous surgery such as percutaneous nephrolithotomy.

Opacification and washout of contrast from the diverticulum may be delayed because of a slow exchange of urine between the collecting system and the diverticulum. Sometimes the diverticulum may fail to opacify due to occlusion of the neck from infection. Urographically, two varieties of diverticulum are described. Type I is situated at the upper pole and communicates with the calyceal cup, usually at the fornix.

These lesions have a bulbous shape with a narrow connecting infundibulum. Type II diverticula communicate with the renal pelvis and may become large enough to produce mass effect. The neck is short and not easily identified [8].

II. Clinical report

A 36-year-old man who presented initially with left flank pain and recurrent urinary tract infection. Plain radiographs had not shown a calculus in the left kidney. Sonography had shown rest of the left kidney, right kidney and urinary bladder were normal.

CT was performed both as a non-enhanced study and after injection of intravenous contrast. The unenhanced CT showed a hypodense area of 5 HU in the left renal lower pole, which after contrast injection showed minimal enhancement with layering of contrast in its dependant portion.

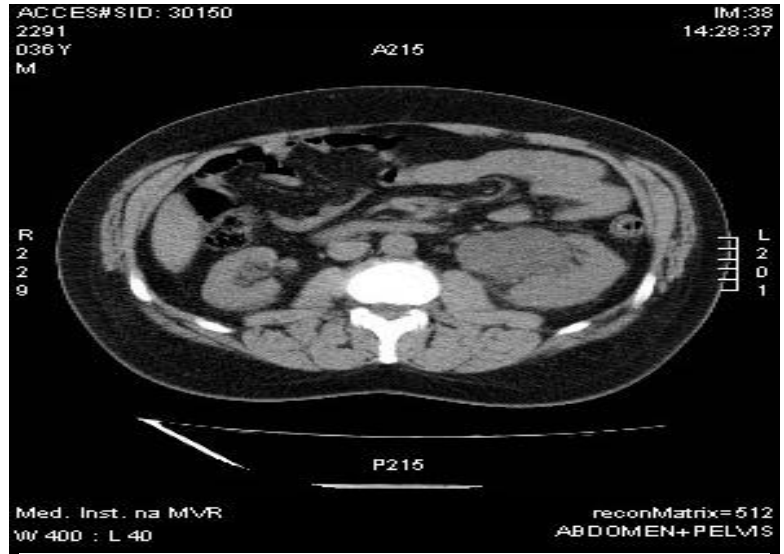


Figure 1. Unenhanced CT showed a hypodense area in the left kidney

The imaging observations were characteristic of Type I Pyelocalyceal Diverticulum in the region of lower pole of left kidney.

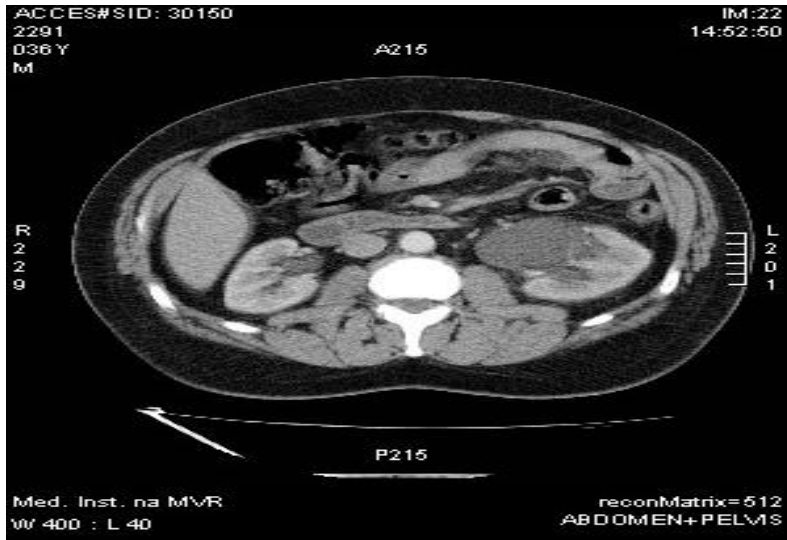


Figure 2. CT showed arterial phase after contrast enhancement

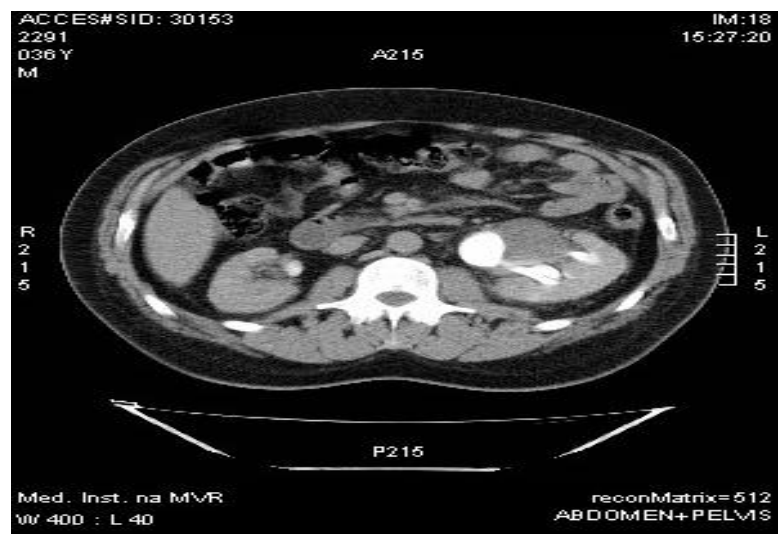


Figure 3. CT showed 10 min after contrast enhancement

Delayed imaging is important as it demonstrates layering of contrast medium within an apparent cystic mass containing calcific densities, which is considered pathognomonic of a calyceal diverticulum (Figure 4 and 5)[7]. Opacification of the diverticulum on delayed imaging also serves to establish patency of the diverticular infundibulum, thereby aiding treatment planning [8] and avoiding the need for retrograde pyelography in some cases.

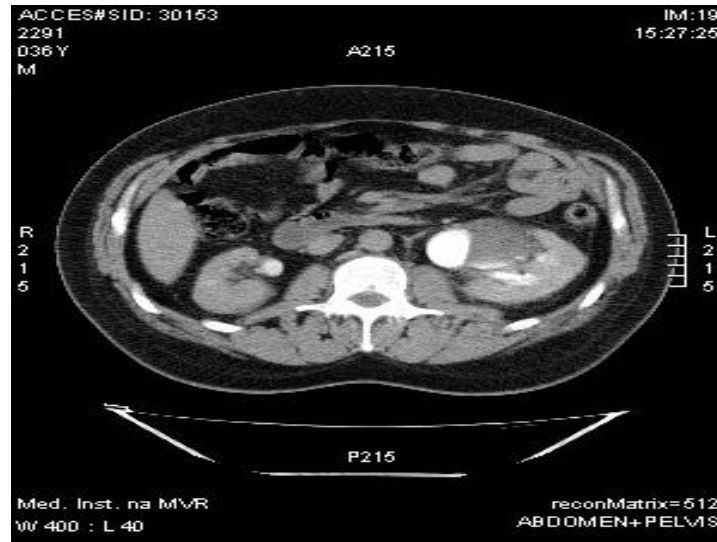


Figure 4. CT showed 30 min after contrast enhancement

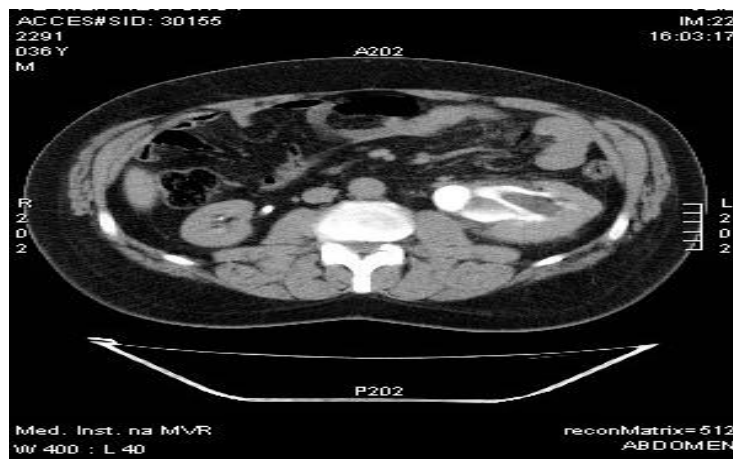


Figure 6. CT showed delayed scans

In particular, the use of reformats can elegantly display the diverticulum and its infundibulum.

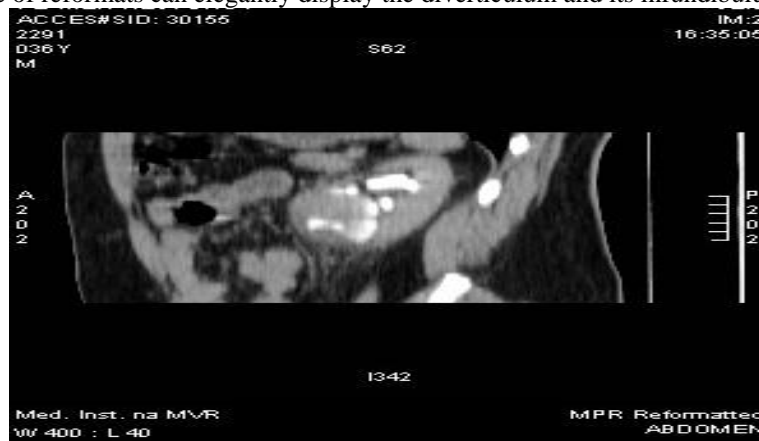


Figure 7. CT showed delayed scans in sagittal reconstruction

III. Discussion

Patients of pyelocalyceal diverticulum are usually asymptomatic, but may complain of hematuria or have symptoms of urinary tract infection, renal colic, pyuria, hypertension or of obstruction due to calculus formation [9].

The presence of a pyelocalyceal diverticulum cannot be envisaged on a plain radiograph because they are radiolucent.

Pyelocalyceal diverticulum has been found in 2.1 to 4.5 per 1000 Intravenous Urographic studies [7]. On Intravenous Urography, the appearance of a pyelocalyceal diverticulum is characteristically that of a contrast filled cystic cavity, which communicates with the renal collecting system and fills with contrast medium by retrograde flow from its connecting calyx or pelvis [3].

Non-contrast CT shows an uncomplicated, regular, fluid-filled space possibly with a thick outer wall, which may contain high attenuation mobile debris due to milk of calcium. Following contrast administration, layering of contrast in the dependant position is noted. The patency of the diverticulum is demonstrated by the gradual opacification on delayed scans [2]. Pyelocalyceal diverticulum may fail to opacify at IVU or CT if infection or scarring obstructs its infundibulum.

Infection, hemorrhage or transitional cell carcinoma arising from its uroepithelial lining are the known complications of a pyelocalyceal diverticulum. As highlighted by Gayer et al [12], following intravenous contrast administration there is a slight increase in density of the cystic lesion. If delayed imaging is not routinely performed, this increase can be mistakenly perceived as “enhancement” of a cystic renal malignancy, rather than early opacification of a calyceal diverticulum.

At radiology and imaging a calyceal diverticulum must be differentiated from hydrocalix, simple cyst, parapelvic cyst, tubercular cavity and papillary necrosis. Hydrocalix refers to irregular calyceal dilatation caused by infundibular obstruction, either acquired or congenital. Hydrocalix is seen in the normal position of the calyx, whereas a pyelocalyceal diverticulum is found in the corticomedullary area.

Multislice CT with its ability to perform multiphase contrast-enhanced scans has led to increased diagnostic accuracy in the evaluation of cystic renal masses. Following administration of intravenous contrast, the attenuation of fluid in the upper part of the cyst increased by approximately 20 Hounsfield units. Delayed imaging demonstrated opacification of the entire lesion with a similar density to that of the CT is a valuable modality in the evaluation of a complicated cystic lesion identified on ultrasound that does not have the typical sonograph appearances of a calyceal diverticulum.

IV. Conclusions

Pyelocalyceal diverticulum has to be considered in the differential diagnosis of patients with pyelonephritis and space-occupying lesion of the kidney.

This case report summarises how calyceal diverticula may mimic serious pathology, leading to diagnostic difficulties.

Once a renal calyceal diverticulum becomes symptomatic, the primary aim of imaging is to accurately localise the diverticulum and to assess if there are calculi within it. Such an analysis will guide a subsequent treatment, whether by radiological intervention, extracorporeal shock-wave lithotripsy (ESWL) or surgical procedures.

A combination of imaging modalities might be necessary to reach a definitive diagnosis in difficult cases, although in most cases the diagnosis can be made by ultrasound.

References

- [1]. GC Prather. Calyceal diverticulum. *J Urol* 1941;45:55
- [2]. MA Wulfsohn. Pyelocalyceal Diverticula. *J Urol* 1980; 123:1-8
- [3]. MJ Siegel, McAlister WH. Calyceal diverticula in children: Unusual features and complications. *Radiology* 1979; 131: 79-82
- [4]. AJ Davidson, DS Hartman, PL Choyke, BJ Wagner. *Davidson's Radiology of the Kidney and Genitourinary Tract*. 3rd ed. Philadelphia: W.B. Saunders Company, 1999: 416-421.
- [5]. V Rathaus, O Konen, M Werner, MS Feinberg, M Grunebaum, R Zissin. Pyelocalyceal diverticulum: The imaging spectrum with emphasis on the ultrasound features. *Br J*
- [6]. N R Surendrababu, S Govil. Diagnostic dilemma: Calyceal diverticulum vs complicated cyst. *Indian J Med Sci* 2005;59:403-5
- [7]. GM Israel, MA Bosniak. Calcification in cystic renal masses: is it important in diagnosis? *Radiology* 2003; 226:47-52.
- [8]. *Radiol* 2001; 74: 595-601.
- [9]. M Jain, SB Grover, A Kumar, NK Mohanty. Images: Pyelocalyceal diverticulum. *Ind J Rad Img* 2004;14:279-81.
- [10]. BS Abeshouse, GA Abeshouse. Calyceal diverticulum: a report of sixteen cases and review of literature. *Urol Int* 1963; 15(6) 329-357.
- [11]. A Kaviani, J Hosseini, B Lotfi, R Valipour, I Sadeghain. Disfiguring abdominal mass due to a huge extraordinary calyceal diverticulum. *Urol J* 2010;7:284-6
- [12]. B Turna, A Raza S, Moussa, G Smith, DA Tolley. Management of calyceal diverticular stones with extracorporeal shock wave lithotripsy and percutaneous nephrolithotomy: long-term outcome. *BJU Int*2007;100:151-6
- [13]. G Gayer, S Apter, Z Heyman, B Morag. Pyelocalyceal diverticula containing milk of calcium — CT diagnosis. *Clin Radiol* 1998;53:369-71